

THE INTERVENTIONALIST JOURNAL

Contents

Volume 4

Number 3

Sept 2024

No.

Title

Page

Original Article

- 1. PRELIMINARY STUDY: ASYMMETRICAL CORTICAL VEIN SIGN (ACVS) PREDICTING NEUROLOGICAL AND RADIOLOGICAL IMPROVEMENT IN LARGE AND DISTAL VESSEL OCCLUSION POST REPERFUSION THERAPY**

A.T. Che Othman, E. Abdul Rahim, M.F.A. Kamis.....1

PRELIMINARY STUDY: ASYMMETRICAL CORTICAL VEIN SIGN (ACVS) PREDICTING NEUROLOGICAL AND RADIOLOGICAL IMPROVEMENT IN LARGE AND DISTAL VESSEL OCCLUSION POST REPERFUSION THERAPY

A.T. Che Othman^{1*}, E. Abdul Rahim¹, M.F.A. Kamis²

¹Department of Radiology, Fakulti Perubatan & Sains Kesihatan, Universiti Putra Malaysia, 43400 UPM Serdang, Selangor

²Department of Radiology, Hospital Sultan Abdul Aziz Shah, UPM, Persiaran Mardi, 43400 Serdang, Selangor

*Corresponding author:

Azlin Tasnim Che Othman, Department of Radiology, Fakulti Perubatan & Sains Kesihatan, Universiti Putra Malaysia, 43400 UPM Serdang, Selangor, Malaysia. Email: azlintasnim@gmail.com

DOI: <https://doi.org/10.32896/tij.v4n3.1-9>

Submitted: 03.07.2024

Accepted: 19.09.2024

Published: 30.09.2024

ABSTRACT:

Purpose

To investigate the dynamic changes in ACVS on SWIs in patients who underwent reperfusion therapy and evaluate their association with neurological and radiological improvement.

Materials and Methods

All patients treated for acute ischemic stroke between June 2020 and June 2022, in a single tertiary centre (Hospital Sultan Abdul Aziz Shah) who underwent reperfusion therapy and MRI imaging were retrospectively identified based on clinical and radiology reports.

Expected Results

This study hypothesizes an improvement in ACVS is expected to correlate with favourable neurological outcomes (MRS at 3 months and NIHSS score) and radiological outcome (DWI / ASPECT scores and Modified Mori score). Conversely, a worsening of ACVS is anticipated to be associated with unfavourable neurological and radiological outcomes.

Conclusion

Asymmetrical Cortical Vein Signs (ACVS) can serve as a valuable predictor of neurological and radiological outcomes in patients with large and distal vessel occlusion after reperfusion therapy.

Keywords: Asymmetrical cortical vein sign (ACVS), Ischemic penumbra, Large vessel occlusion (LVO), Distal vessel occlusion (DVO)

INTRODUCTION

Stroke has become a major public health concern in Malaysia. The incidence of stroke is increasing annually, making the disease the second leading cause of death and the highest disability rate in the nation (1). Nearly two-thirds of reported strokes in Malaysia were ischemic in origin, while the remaining third were haemorrhagic which includes intracerebral and subarachnoid hemorrhag (2). The Academy of Medicine of Malaysia (2021) recently updated its clinical practice guidelines for ischemic stroke, providing recommendations based on Level I - II evidence. These guidelines emphasize the importance of a timely approach for the prompt delivery of reperfusion therapy, including intravenous thrombolysis and endovascular therapy. Timeliness is crucial in ensuring optimal outcomes for patients with ischemic stroke. Whereas traditional selection of reperfusion therapy was based on a strict time window, recent studies have shown that reperfusion therapy has significant benefits when delivered in a timely manner. In addition, advances in neuroimaging have led to a shift in patient selection to tissue-based imaging, made possible by the identification of the ischemic penumbra.

The ischemic penumbra is characterized by decreased, but not absent, blood flow and metabolic function and is at risk for infarction but can be salvaged by reperfusion therapy (3). The penumbra is not a static entity but rather a constantly changing region of brain tissue at risk of infarction. Its fate is influenced by several factors, including the duration and severity of the ischemic insult, the extent of collateral circulation, and the effectiveness of reperfusion therapy. imaging modalities commonly used in the evaluation of acute ischemic stroke include computed tomography (CT) and magnetic resonance imaging (MRI) have been used to identify the ischemic penumbra and guide treatment decisions (4). Various imaging modalities, such as diffusion-weighted imaging (DWI) and perfusion-weighted imaging (PWI), have been used to detect and quantify the extent of ischemic injury and penumbra in patients with acute ischemic stroke. However, these modalities

have limitations in terms of availability, cost, and interpretation. In addition, identification of penumbra remains challenging because of its dynamic nature and the lack of a reliable biomarker.

The Asymmetrical cortical vein sign (ACVS) is a radiological phenomenon that has become increasingly useful in identifying ischemic penumbra. Research investigations have explored the association between the Asymmetrical Cortical Vein Sign (ACVS) and other factors or outcomes. Haacke et al. (2009) denotes ACVS as enhanced venous signals in the cerebral cortex on one side of the SWI, exceeding those observed on the opposite side. which may suggest the presence of the ischemic penumbra. The mechanism behind the appearance of ACVS is thought to be related to reduced oxygen extraction fraction (OEF) in hypoperfused tissue, leading to a decrease in deoxyhemoglobin concentration and sensitivity effects in venous blood (5,6). Several studies have suggested that ACVS may be a useful marker for identifying at-risk tissues in acute ischemic stroke and predicting clinical outcome. However, there are limited data on the dynamic changes of ACVS after reperfusion therapy and its correlation with neurological and radiological improvements. Understanding the evolution of ACVS after reperfusion therapy could provide important insights into the pathophysiology of ischemic stroke and help identify patients most likely to benefit from reperfusion therapy.

This preliminary study aims to examine the fluctuating patterns of ACVS on SWI in individuals receiving reperfusion therapy for acute ischemic stroke, followed by evaluating how variations in ACVS correlate with improvements in neurological and radiological conditions. Furthermore, there is a need to investigate the potential of ACVS as a biomarker to forecast outcomes in hyperacute stroke cases. Last but not least, this research aims to deepen insights into ischemic stroke mechanisms and potentially identify a pivotal biomarker for predicting outcomes in reperfusion therapy recipients.

MATERIALS AND METHOD

This cross-sectional study will analyze clinical data from consecutive patients diagnosed with acute ischemic stroke who underwent brain MRI within 24 hours of symptom onset and received follow-up MRI within 1 week of post-reperfusion therapy at Hospital Pengajar University Putra Malaysia (HPUPM) between June 1, 2020 and June 1, 2022. The sample size of 29 was determined using the UCSF Clinical Translation Science Institute calculator. The study will include patients with large vessel occlusion (LVO) and distal vessel occlusion (DVO) who received either intravenous thrombolysis, mechanical thrombectomy, or both. MRI imaging will be performed using a 3.0 Tesla Philips Ingenia machine, employing sequences such as DWI, FLAIR, MR Angiography, SWI, and 3D pCASL. Clinical and demographic data will be collected from electronic hospital information systems. Two experienced radiologists will independently review MRI images to assess ACVS changes and ensure interobserver reliability. The study will evaluate neurological outcomes using the National Institutes of Health Stroke Scale (NIHSS) pre- and post-treatment, as well as the Modified Rankin Scale (MRS) at 3 months post-stroke. Radiological outcomes will be assessed using DWI Alberta Stroke Program Early CT Score (ASPECT) pre- and post-treatment, and Modified Mori (MORI) scores.

LITERATURE REVIEW

In ischemic stroke, the blockage of a major or distal cerebral artery reduces blood flow and causes a deficiency of oxygen in the affected brain tissue. Powers and colleagues have categorized these changes into three stages of hemodynamic impairment, illustrating the dynamic response of cerebral blood flow to decreasing cerebral perfusion pressure (CPP). Initially, when CPP is normal, cerebral blood flow (CBF) adjusts to meet brain tissue metabolic needs without altering oxygen extraction fraction (OEF). As CPP declines further, the brain compensates by dilating cerebral arterioles to maintain CBF (stage 1).

However, continued CPP reduction overwhelms these mechanisms, progressing to stage 2 where CBF further declines and OEF rises as the brain tries to extract more oxygen from limited blood supply to meet metabolic demands. This elevated OEF and reduced CBF heighten the risk of tissue damage and infarction (4).

The neurovascular unit has traditionally focused on capillaries and their surrounding cells, downplaying the significance of veins in circulation and their role in acute brain injury. Recent studies underscore the critical role of the broader vascular system—arteries, arterioles, veins, and venules—in supplying and draining blood to and from capillaries (7). While capillaries facilitate nutrient and oxygen exchange, the venous system is crucial for removing waste products like carbon dioxide. It regulates blood flow, maintains blood pressure, and transports blood within the brain. Cerebral venous fluctuations can lead to venous congestion, increasing intracranial pressure (ICP). Elevated ICP can breach the blood-brain barrier (BBB), permitting toxic substances and immune cells from the bloodstream to enter brain tissue, exacerbating conditions such as infarction or hemorrhage (8).

Oxygen extraction fraction (OEF) quantifies the oxygen taken from arterial blood by the brain, crucial for assessing brain metabolism and function in neurological disorders such as stroke, traumatic brain injury, and brain tumors. Typically, OEF ranges from 30-40%, indicating the brain's oxygen uptake from blood. Under conditions like hypoxia, ischemia, or metabolic disorders, OEF may increase to ensure adequate brain oxygenation. PET with oxygen-15-labeled gases provides precise imaging of cerebral oxygenation, albeit at high cost and invasiveness. Studies demonstrate that the BOLD effect correlates with both GRE and SWI due to deoxyhemoglobin's paramagnetic properties, causing signal intensity reduction. Factors such as deoxyhemoglobin concentration and microvasculature size influence this effect. Figure 1 illustrates the biomechanics of the acute cortical venous stroke (ACVS) based on the principles of

the BOLD effect in susceptibility-weighted imaging (SWI).

Lu et al. (2021) conducted a systematic review and meta-analysis of 16 studies published from 2011 to 2020, focusing on evaluating different methodologies used in assessing acute cortical venous stroke (ACVS) via susceptibility-weighted imaging (SWI) (9). Their findings revealed four primary approaches: visual assessment, ASPECT assessment, pixel assessment, and slice assessment. Visual assessment was the most commonly employed method, despite its limitations in comparing ACVS with the contralateral hemisphere. ASPECT assessment, although less utilized, provides a quantitative scoring system to categorize patients into SWI-ACVS positive groups, yet its predictive value remains unclear. Studies employing pixel scoring compared venous signal intensity between hemispheres, while a single study used a slice method defining SWI-PVS positivity based on specific criteria. Few studies, such as Bhattacharjee et al., have explored the reliability of SWI/DWI mismatch compared to PWI/DWI, yielding inconsistent results regarding their association with perfusion deficits. Table 1 summarizes the study characteristics and quality assessments, offering insights into the methodologies and reliability of ACVS-SWI findings (9).

EXPECTED RESULTS

This study proposes that alterations observed in acute cortical venous stroke (ACVS) on post-treatment SWI will correlate with both neurological and radiological improvements in patients with large vessel occlusion (LVO) and distal vessel occlusion (DVO) following reperfusion therapy. Figures 2 and 3 depict the progression of ACVS signs, illustrating scenarios of both worsening and improving conditions. Specifically, improvement in ACVS is anticipated to align with favorable neurological outcomes, assessed by the Modified Rankin Scale (MRS) at 3 months, and positive radiological outcomes, evaluated using DWI ASPECT scores.

Conversely, deterioration in ACVS is expected to correlate with unfavorable neurological outcomes and potentially with radiological findings indicative of larger infarct volumes.

CONCLUSION

This preliminary study explores the dynamic changes in acute cortical venous stroke (ACVS) and its association with treatment response in patients undergoing reperfusion therapy for ischemic stroke. By analyzing ACVS progression on susceptibility-weighted imaging (SWI), this research contributes to the broader understanding of ischemic stroke pathophysiology. The findings suggest that ACVS could serve as a potential biomarker for predicting neurological and radiological outcomes following reperfusion therapy. Further studies are warranted to validate these preliminary findings and elucidate the clinical utility of ACVS in improving stroke management strategies.

CONFLICTS OF INTEREST

The authors have no potential conflicts of interest to disclose and are in agreement with the contents of the manuscript.

FUNDING

This article did not receive specific funding.

REFERENCES

1. Aziz ZA, Sidek NN, Kamarudin MK, Baharum N, Muneer A, Hamid A, Lutfi A, Yusoff M, Ibrahim KA. Annual Report of the Malaysian.
2. Neelamegam M, Looi I, Cheah WK, Narayanan P, Hamid AM, Ong LM. Stroke incidence in the South West District of the Penang Island, Malaysia: PEARLS: Penang Acute Stroke Research Longitudinal Study. *Prev Med.* 2013;57 Suppl–S79.
<https://doi.org/10.1016/j.ypmed.2012.12.022>

3. Astrup J, Siesjö BK, Symon L. Thresholds in cerebral ischemia - the ischemic penumbra. *Stroke*. 1981;12(6):723–725. <https://doi.org/10.1161/01.str.12.6.723>
4. Powers WJ, Rabinstein AA, Ackerson T, Adeoye OM, Bambakidis NC, Becker K, et al. 2018 Guidelines for the early management of patients with acute ischemic stroke: a guideline for healthcare professionals from the American Heart Association/American Stroke Association. *Stroke*. 2018;49(3)–e110. <https://doi.org/10.1161/STR.0000000000000158>
5. Haacke EM, Mittal S, Wu Z, Neelavalli J, Cheng YC. Susceptibility-weighted imaging: technical aspects and clinical applications, part 1. *AJNR Am J Neuroradiol*. 2009;30(1):19–30. <https://doi.org/10.3174/ajnr.A1400>
6. Fan AP, Khalil AA, Fiebach JB, Zaharchuk G, Villringer A, Villringer K, Gauthier CJ. Elevated brain oxygen extraction fraction measured by MRI susceptibility relates to perfusion status in acute ischemic stroke. *J Cereb Blood Flow Metab*. 2020;40(3):539–551. <https://doi.org/10.1177/0271678X19827944>
7. Chen, S., Chen, Y., Xu, L., Matei, N., Tang, J., Feng, H., & Zhang, J. (2015). Venous system in acute brain injury: Mechanisms of pathophysiological change and function. *Experimental neurology*, 272, 4–10. <https://doi.org/10.1016/j.expneurol.2015.03.007>
8. Stam J. (2005). Thrombosis of the cerebral veins and sinuses. *The New England journal of medicine*, 352(17), 1791–1798. <https://doi.org/10.1056/NEJMra042354>
9. Lu P, Cui L, Zhao X. The prognostic impact of susceptibility-weighted imaging prominent veins in acute ischemic stroke: a systematic review and meta-analysis. *Neuropsychiatr Dis Treat*. 2021;17:3069–3079. <https://doi.org/10.2147/NDT.S331874>

TABLE LEGENDS:

Table 1: General study characteristics and quality assessment aspects of the included cohort studies to ACVS-SWI. Adapted from Lu et al. (2021).

Study	Design	Control for Confounders	Inclusion Criteria (AIS with Occlusion/ Stenosis or Without)	Analysis Method of PVS-SWI	All	Outcomes
Sun W et al 2014 ¹⁰	P	N- Control	Without SILASO	Visual assessment	572	90-day MRS, 72-hour NI \geq 2
Yu J et al 2017 ¹¹	R	N- Control	With MCA occlusion or stenosis	Visual assessment	124	90-day MRS
Wang Y et al 2018 ¹²	R	Not reported	With MCA occlusion	Visual assessment	40	90-day MRS
Zhao G et al 2017 ¹³	R	Control	Without SILASO	Pixel assessment	60	90-day MRS, HT
Yu X et al 2016 ¹⁴	P	N- Control	Without SILASO	Pixel assessment	33	90-day MRS
Zhang X et al 2017 ¹⁵	R	N- Control	Without SILASO	Pixel assessment	109	90-day MRS
Jing L et al 2021 ¹⁶	R	N- Control	Without SILASO	ASPECT assessment	47	7-day MRS, HT
Vural A et al 2016 ¹⁷	R	Not reported	With MCA occlusion	Slice assessment	50	Discharge MRS
Li W et al 2020 ¹⁸	R	Not reported	With SILASO	Visual assessment	109	72-hour NI \geq 2
Liu YL et al 2020 ²⁷	P	Control	With SILASO	Visual assessment	55	90-day MRS, HT
Liu YL et al 2020 ¹⁹				ASPECT assessment	61	48-hour NI \geq 2
Hu Zongji et al 2020 ²⁰	R	Control	Without SILASO	Visual assessment	133	7-day NI \geq 2
Liu H et al 2018 ²¹	R	N- Control	With MCA occlusion or stenosis	ASPECT assessment	30	90-day MRS
Chen CY et al 2015 ²²	P	Not reported	Without SILASO	ASPECT assessment	22	90-day MRS
JIA Ya-Nan et al 2019 ²³	P	N- Control	Without SILASO	Visual assessment	125	90-day MRS
Wang C et al 2017 ²⁴	R	Control	With MCA occlusion	Visual assessment	46	90-day MRS, HT
P H et al 2011 ²⁵	P	Control	Without SILASO	Visual assessment	44	180-day MRS, HT

FIGURE LEGENDS:

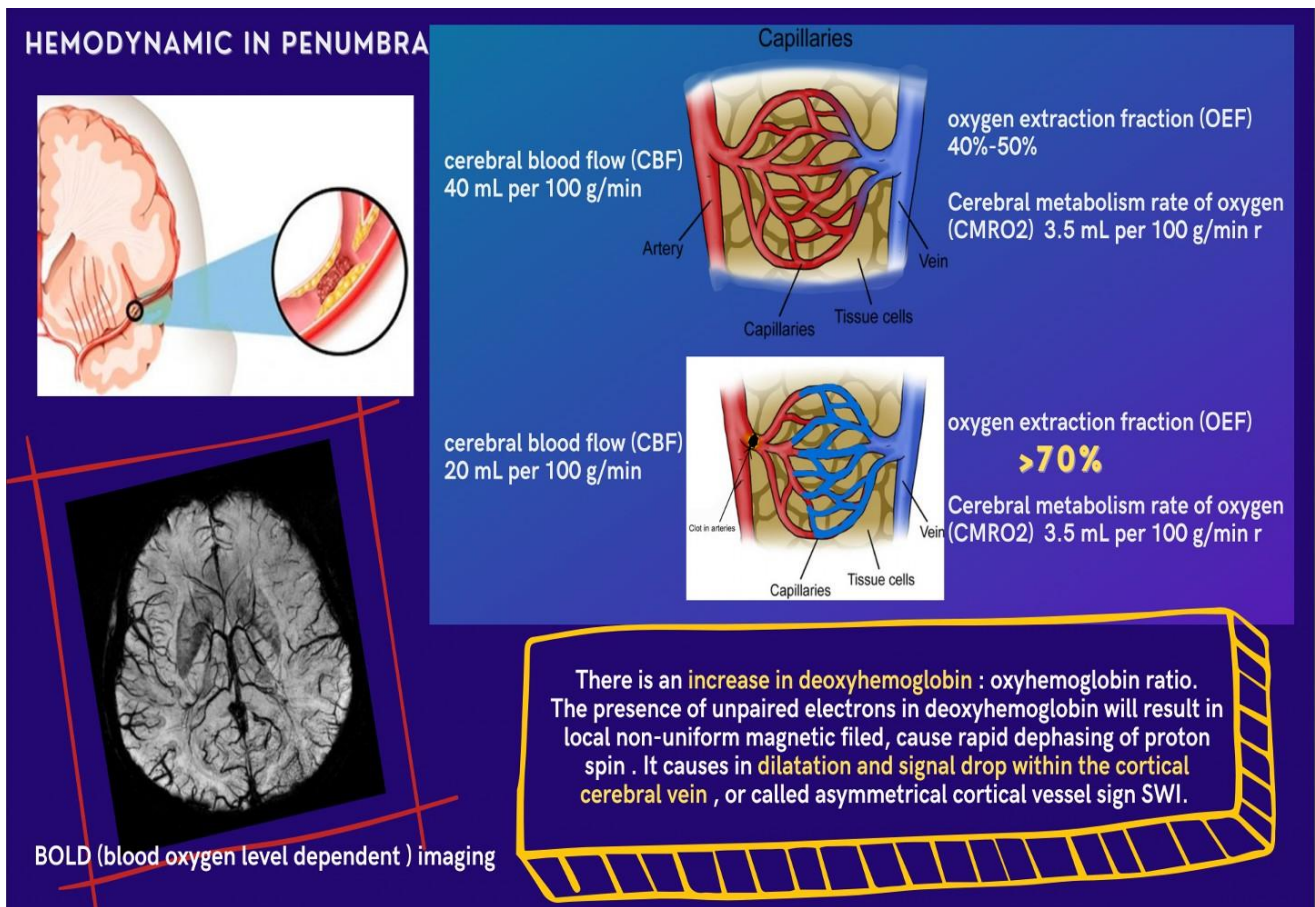


Figure 1: Biomechanics of the ACVS according to the principle of the BOLD effect in SWI.

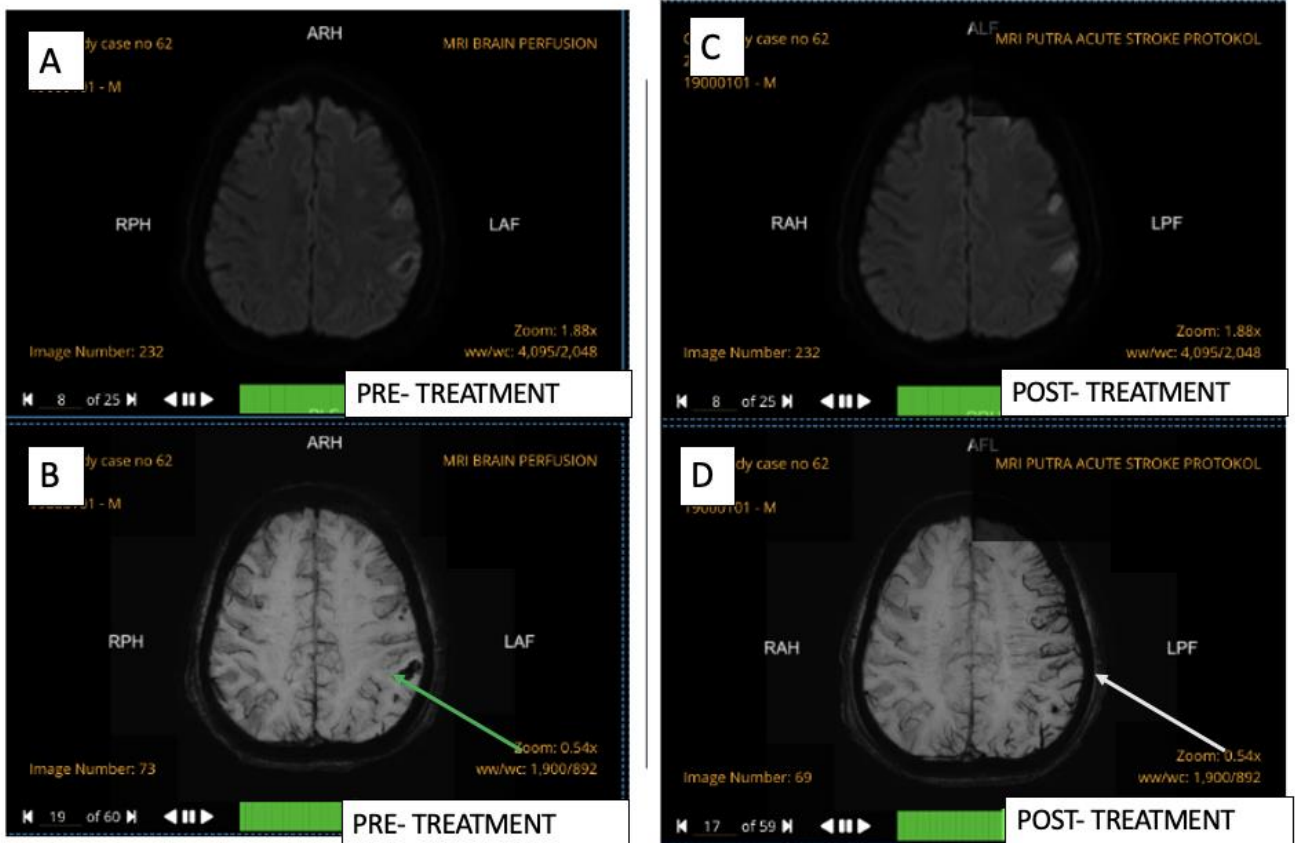


Figure 2: Worsening ACVS. Figure 2A: DWI. Figure 2B: SWI pre-treatment shows left cerebral infarction with ACVS sign in pre-treatment study (green arrow). Figure 2C: ADC. Figure 2D: SWI post-treatment shows increasing ACVS on the left cerebral hemisphere (white arrow).

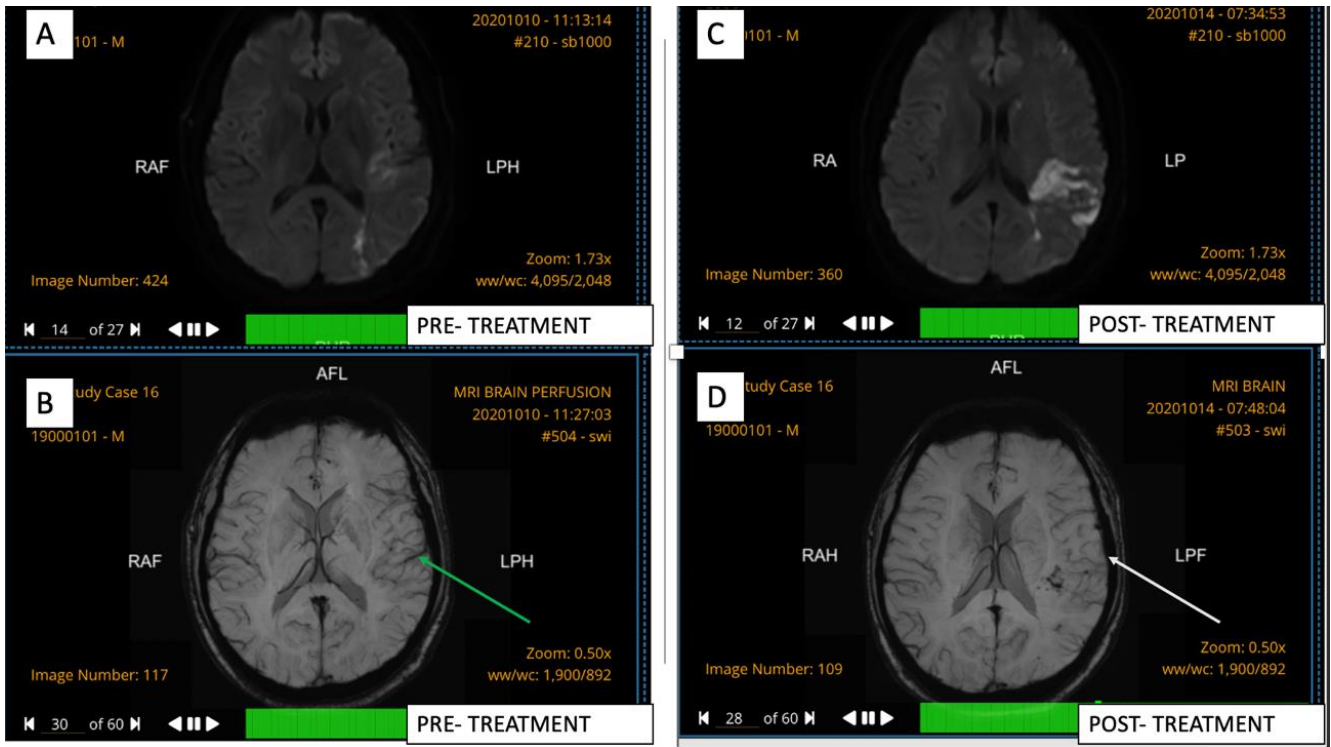


Figure 3: Improving ACVS. Figure 3A: DWI. Figure 3B: SWI pre-treatment shows left cerebral infarction with ACVS sign in pre-treatment study (green arrow). Figure 3C: ADC. Figure 3D: SWI post-treatment shows equal/less ACVS on the left cerebral hemisphere compared to pre-treatment study (white arrow).